

Background & Rationale

Great apes share many behavioral, cognitive, and neuroanatomical similarities with humans. Yet, there are also significant differences that distinguish humans from apes in terms of cognitive specializations and their underlying neurobiological basis. The goal of the **Great Ape Neuroscience Project** is to investigate the neurobiological variation that distinguishes great apes from other primates, defines each great ape species as unique, and helps us to better understand humans' place in nature. The Great Ape Neuroscience Project, which is the continuation of the Great Ape Aging Project (GAAP), has been active for over a decade and it is well supported by a core of scientific collaborators (Joseph Erwin, Patrick Hof, Bill Hopkins, Mary Ann Raghanti, and Chet Sherwood), strong external grant funding for research (NIH, NSF, James S McDonnell Foundation, Wenner-Gren Foundation), and a track-record of substantial publication, data sharing, and student training.

The current proposal aims to extend the previous Great Ape Aging Project (GAAP), headed by Dr. Joseph Erwin. A Progress Report of the previous work and findings are attached to this application. The long-term goal of this project is to characterize the neurobiological organization of the brains of all great apes by collecting post-mortem specimens from individuals who had been under the care of North American Zoos. Pragmatically, the aim of the project is to obtain a sufficient number of brains from different age and sex classes of gorillas, chimpanzees, bonobos, and orangutans that will provide statistical power to make strong comparisons among species, and with human specimens in the context of brain aging. Furthermore, although the PIs of this project have their own scientific interest in these brains, the larger goal is to provide a database and specimen bank for making tissue samples and magnetic resonance images of the brains available to the scientific community.

There is a compelling scientific need for this effort. There is a tendency in the anthropological, psychological, and neuroscience literatures to lump all apes together for comparison to humans and other primates. In large part, this is due to the relatively small samples of different ape species that have been available for studies of neurobiology and cognition. This is unfortunate, because the different species of great apes have each adapted distinctive behavioral strategies that are suited to their different ecological niches and social structures. Thus, the degree of similarities and differences between great apes in brain organization and how that might relate to specific cognitive or motor adaptations remains poorly understood. These data are critical for understanding the unique s of great apes, the possible, and specific, vulnerability of each species to neuropathological disorders, and would potentially serve as important information for public education in conservation efforts. For example, humans show marked age-related decline in cortical organization, cognitive, and motor function, whereas chimpanzees show far less evidence for behavioral and cognitive decline with increasing age. Whether this represents a unique characteristic of chimpanzee brain aging or is a more general difference between humans and all apes remains at present unknown. Neurological and behavioral data from all great apes are important for addressing this, and other, questions.

To facilitate the success of this project, we are requesting, through APETAG, participation from all zoos housing great apes in North America. When an ape dies at any of the zoos, we are proposing that the brains be extracted and processed where

upon a standardized and consistent set of post-mortem analyses will be performed on the brains. Procedurally, there are two basic components to the proposed studies. First, the brains will be MRI scanned using a high-field scanner (7 Tesla) in the laboratory of Dr. Hopkins. This procedure will allow for detailed 3D anatomical measures of the brain and will preserve an archive of the intact morphology prior to further histological processing. Following the scanning, the brains will be shipped to the laboratories of Dr. Sherwood, Hof, or Raghanti for subsequent histological analyses. These laboratories will serve as a resource archive for providing tissue to other scientists that make requests for samples. All brains, regardless of the location of their final disposition, will be inventoried in a common database. The specific procedures are outlined below.

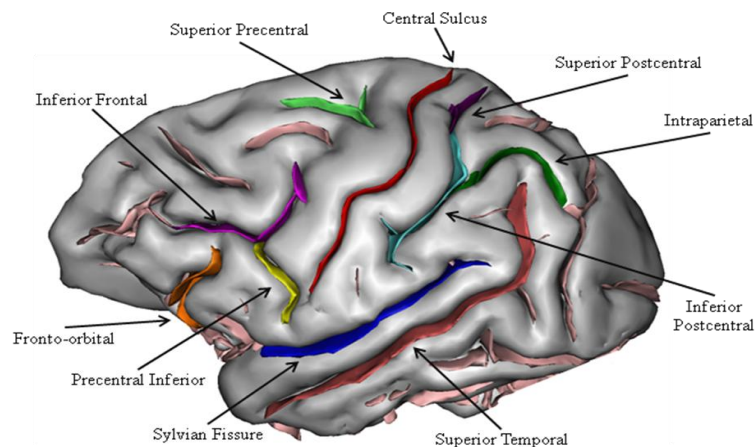
Whole fixed brains are best suited for MRI scanning prior to histological sectioning for research and pathology diagnosis. However, if the postmortem interval before brain collection is less than 5 hours, we request that, as much as feasible, the left hemisphere be fixed and the right hemisphere be snap-frozen or placed in RNAlater. When brain tissue specimens are provided, we will make every effort to secure a collaborating neuropathologist to provide a detailed neurological report to the institutional veterinarian. Alternatively, we will coordinate dissection and sampling directly with the originating institutions in case they desire performing their own neuropathologic examination and we will return sufficient materials for the diagnostic procedures. We will also provide a high-quality 7 T MRI of each brain, if it is received intact. Note that a 7 T Bruker instrument is also available to Dr Hof at Mount Sinai school of Medicine, increasing the scanning capacity of this project.

MRI Scanning and Post-Mortem Analyses of Great Ape Brains

MRI Scanning

MRI scanning of cadaver specimens will involve the use of a 7 Tesla MRI scanner (GE) housed at the Yerkes National Primate Research Center. T2-weighted images will be collected for the entire brain using a gradient echo protocol. The archived data will be stored on optical

diskettes and transported to a PC workstation where multiplanar reformatting software (ANALYZE) will be used to align the scans in the coronal, sagittal and transverse planes. The T2 images will then be cut into 1-mm sagittal, axial and coronal slices for post-image processing. Post-image analyses will be performed using ANALYZE. For each brain region, measures will be obtained from the left and right hemispheres. Measures to be obtained from the brains will include brain volume, grey and white



matter volume, cortical folding and grey matter thickness. In addition, measures of sulci depth and surface area will be obtained from each brain (see Figure). Lastly, a number of regions of interest will be quantified in the different ape brains including the: hippocampus, amygdala, caudate, putamen, cerebellum, motor-hand area of the precentral gyrus, inferior frontal gyrus, planum temporale, and prefrontal cortex.

Histological and Molecular Analyses

Because part of our research involves analyses of asymmetries, it is particularly important that we obtain whole brains because we need samples from homologous regions from both hemispheres (note: when the postmortem interval before brain collection is less than 5 hours, we request the left hemisphere fixed and the right hemisphere frozen or in RNAlater after cutting into 3 cm-thick coronal slabs). As described above, we have and will continue to initially scan the post-mortem brain at 7 T then conduct the histological studies described below.

For our histological and molecular studies, we would ideally like to obtain the entire brain specimen. However, if this were not feasible, then considering our current research studies, we would prioritize collection of the following regions of interest.

First tier of sample collection -

Whole brain*

*If postmortem interval is less than 5 hours, formalin fix the left hemisphere and freeze the right hemisphere, if possible

Second tier of areas to collect -

- 1) Left and right inferior frontal gyrus (Brodmann's areas 44, 45)
- 2) Left and right inferior planum temporale (area 22)
- 3) Left and right motor-hand area of the precentral gyrus (area 4)
- 4) Left hemisphere only: frontal pole (area 10), anterior cingulate cortex (area 24), postcentral gyrus (areas 1-3), and visual cortex (areas 17 and 18)

Third tier of areas to collect -

- 1) Left and right insula
- 2) Left hemisphere only: Brodmann's areas 11, 39 and area 6 medial
- 3) Left hemisphere only: posterior cingulate and retrosplenial cortex (areas 23, 30, 29, 26)
- 4) Left hemisphere only: caudate nucleus
- 5) Left hemisphere only: cerebellum

From these regions, we will determine whether the morphology of supragranular pyramidal neurons differs among hemispheres and cortical areas (inferior frontal gyrus – areas 44 and 45, planum temporale – area 22, precentral gyrus – area 4, Heschl's gyrus (primary auditory cortex) – areas 41/42, and primary visual striate cortex – area 17) in great apes. We will also examine whether there are asymmetries in the morphology of medium spiny neurons in the head of the caudate nucleus, a brain region

that is important for language function and which is a principal target of *FOXP2* gene expression.

Procedure

As we have done in our previous studies with chimpanzee brains, Golgi staining and neuron reconstruction will come from individuals for which a necropsy was performed within 24 hours after death. Brains will be stored phosphate buffer saline (PBS) solution 0.1% azide at 4° C until staining. We have found that tissue maintained in way provides excellent quality of Golgi staining (see FIGURE 1 of chimpanzee neuron). In keeping with previous research in humans as well as our preliminary studies, all tissue will be processed by a modified rapid Golgi

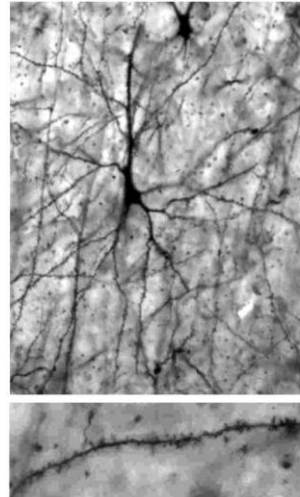


Figure 2

only

in a
with

this

technique and then sectioned at 120 μm with a vibratome. All tissue blocks will be coded to prevent observer bias during measurement. Ten supragranular pyramidal neurons per region of interest in each brain will be selected for quantitative analyses. In the head of the caudate nucleus, we will analyze medium spiny neurons. Criteria for selection requires that neurons be fully impregnated, relatively isolated and unobscured, with the soma centered within the 120- μm section, and dendritic systems as complete as possible. To ensure relative homogeneity in the size of the neurons sampled, the soma depth of each cell from the pial surface will be recorded, and comparable average depths will be maintained across regions. All neurons will be manually traced using a 63x oil objective on a Zeiss Axioplan 2 photomicroscope coupled to a Dell PC workstation running MBF Bioscience NeuroLucida software. Tracing will involve drawing the contour of the soma, following all dendrites along their entire length, and marking all visible spines. Neuronal morphology will be quantified according to six measures: (1) cell soma area (μm^2); (2) total dendritic length (TDL, μm)— the sum of the individual lengths of all dendritic segments; (3) dendritic segment count (DSC)— the number of all dendritic segments; (4) mean segment length (MSL, μm); (5) dendritic spine number (DSN)—the number of all spines marked on the dendritic arbor; (6) spine density (DSD)—the ratio of spines per unit (μm) of dendritic length. For each of these measures, values for the basilar and apical dendrites will be computed separately. As most apical dendrites are incomplete in cut sections, quantitative analyses will focus on basilar arbors. In addition to these measures, a Sholl analysis will be performed, which assesses neuronal morphological complexity as the number of intersections made by each dendritic tree with a series of concentric virtual spheres at increasing increments of 20 μm . An example of a Golgi impregnated neuron from primary visual cortex of a chimpanzee, a close-up of spines on the dendritic shaft, and a NeuroLucida tracing of another neuron are shown in Figure 2.

Other studies will also be performed with these samples using immunohistochemistry and Western blotting to examine the distribution of different molecules related to synaptic function, neurotransmission, and age-related changes in expression. Additional studies of specific neuronal populations identified by neurochemical or molecular markers, and quantitative neuropathologic assessments of age-related changes are also carried out routinely using state-of-the-art stereologic methods in our laboratories.

Ideally, at some point in time, it might also be ideal to consider collection of behavioral data from the apes housed in participating institutions. There are a number of simple motor and cognitive tests that can be employed with the apes that might be useful for correlation with the brain imaging, anatomical, histological, or neuropathological quantitative data to be collected in this proposal. We are presently seeking external funding for this potential aspect of the project and, if successful, we will request zoo participation through APETAG at a later point in time.

Brain Disposition

All brain specimens received for this project will be considered "on loan", meaning that ownership remains with the institution of origin. Each institution should specify how it wishes to be acknowledged in publications.

Only a portion of the total number of histological sections that are produced will be used in the proposed studies. Tissue sections not used immediately in staining experiments will be kept in anatomical order in separate numbered Eppendorf tubes and archived in a freezer storage solution consisting of glycerol, ethylene glycol, dH₂O, and phosphate buffer (3:3:3:1 volume/volume) at -20°C to preserve antigen availability for future experiments and stereologic studies. Careful archiving of these sections will greatly facilitate future investigations of related research topics including analyses of other cortical areas, neurotransmitter systems, and cell phenotypes. The sections in storage will be made available to other researchers upon request. The same storage protocol is used by all PIs. Drs. Hopkins and Sherwood will maintain publicly accessible databases on their laboratory websites to disseminate information regarding the availability of MRI scans or histological sections.

Summary

Collection of Great Ape brains

1. Whole brain* placed into 10% buffered formalin (4% paraformaldehyde)
 - a. If post mortem interval is less than 5 hours, formalin fix the left hemisphere and freeze the right hemisphere

Participating institutions will receive a copy of the MRI scan of the brain and an annual report of scientific findings and publications.

Primary Contact: Bill Hopkins, Ph.D. (phone: 404-727-8235; e-mail: whopkin@emory.edu)

Secondary Contact: Chet Sherwood, Ph.D. (phone: 202-997-6890; email: sherwood@gwu.edu)

If preferred, we will send the necessary shipping containers, buffers, etc. for all shipment. We will also cover all expenses related to shipping and handling of the post-mortem materials.